Neuroscience C3045: Eye and Brain

Comparative Anatomy of the Eye

Professor M. Glickstein

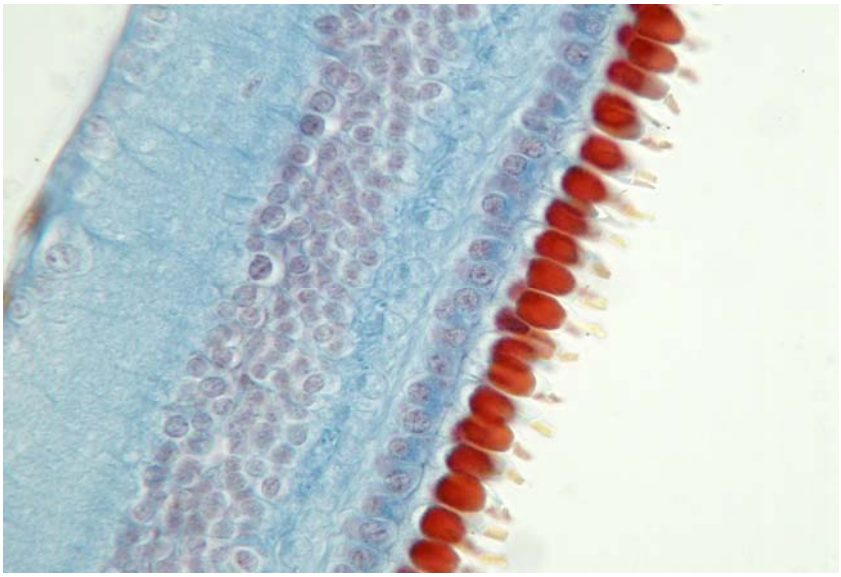

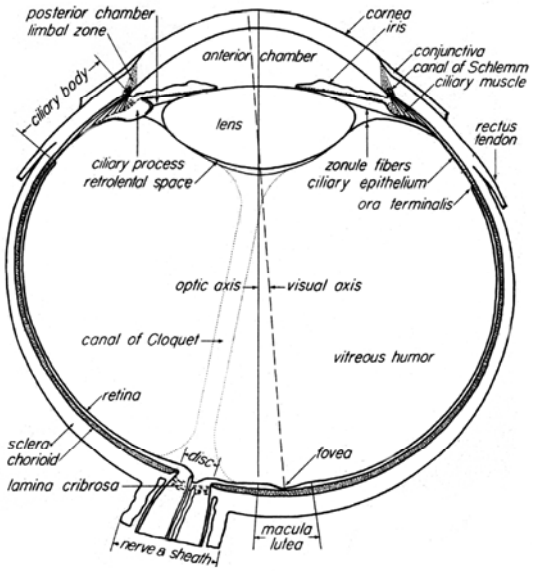
posterior chamber
limbal zone
ciliary body
cornea
iris
anterior chamber
conjunctiva
canal of Schlemm
ciliary muscle
lens
rectus tendon
ciliary process
retrolental space
zonule fibers
ciliary epithelium
ora terminalis
optic axis
visual axis
canal of Cloquet
vitreous humor
retina
sclera
choroid
disc
fovea
lamina cribrosa
macula lutea
nerve a sheath

4 February–19 June 1977
anese Paintings and Prints
Schools of Canku and Bunchō

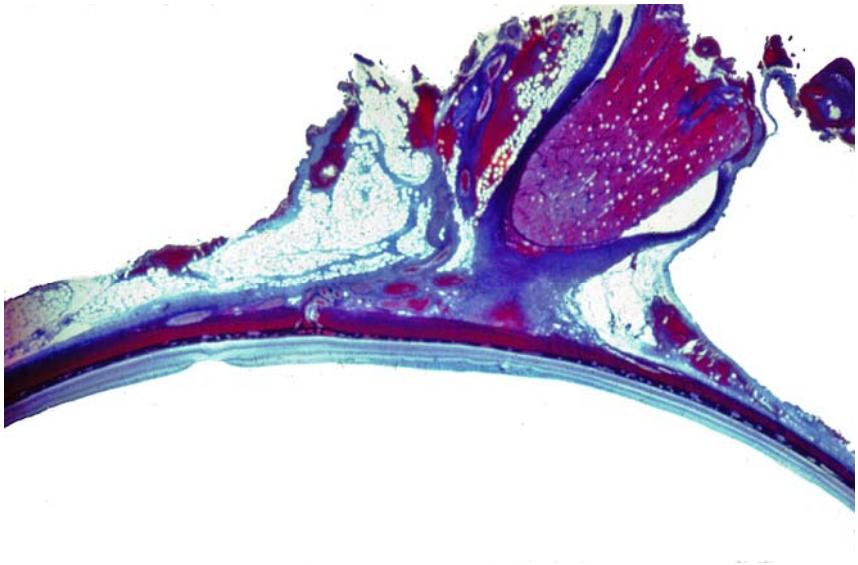

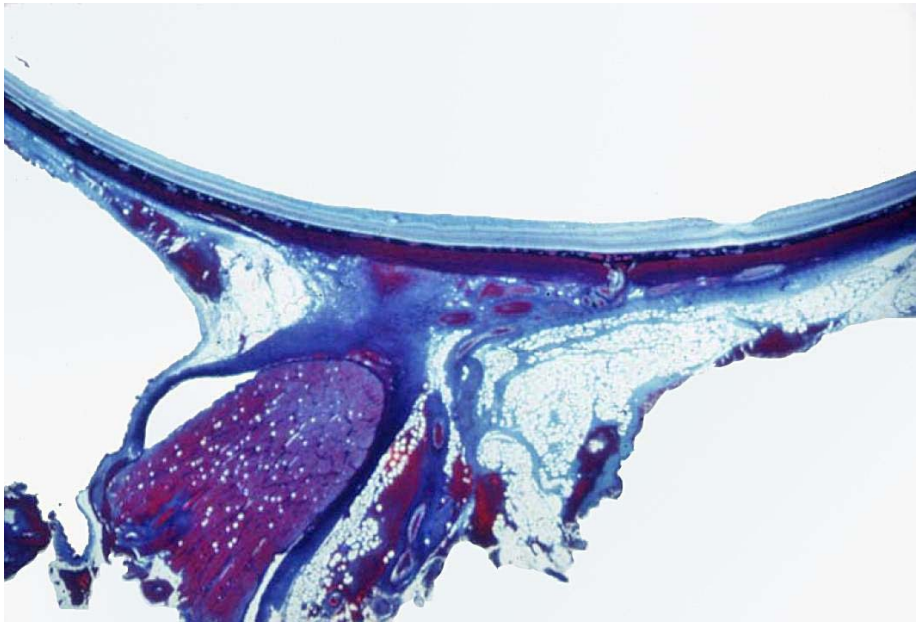

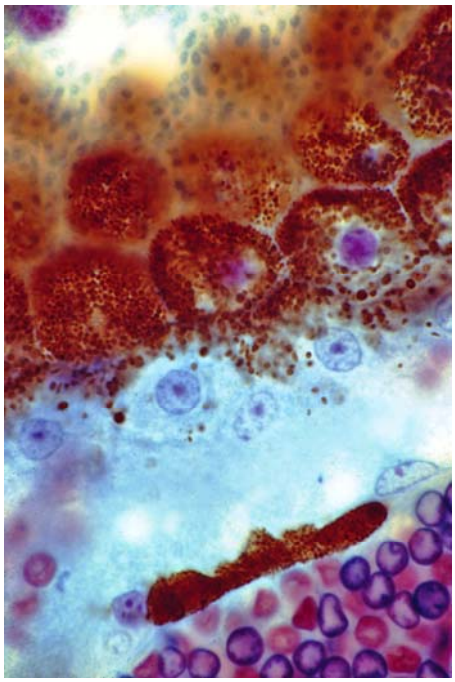

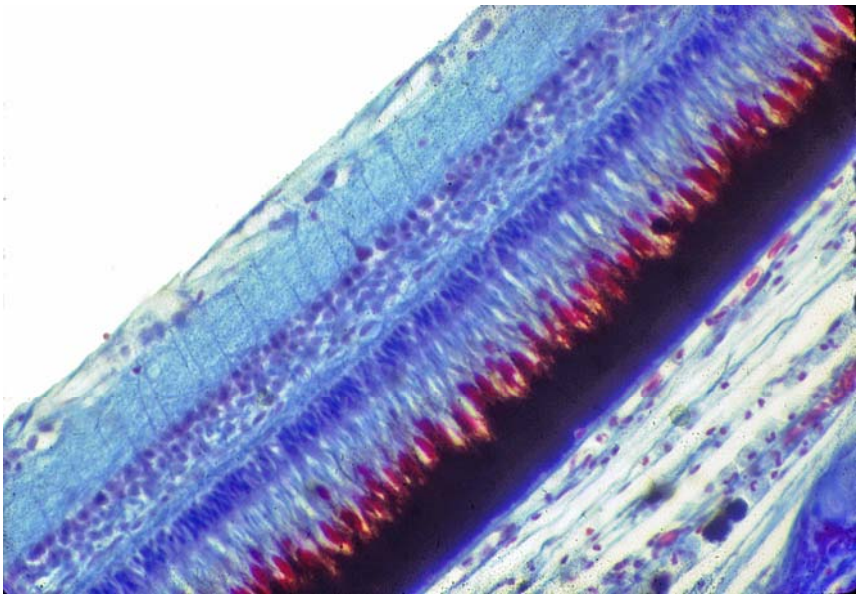

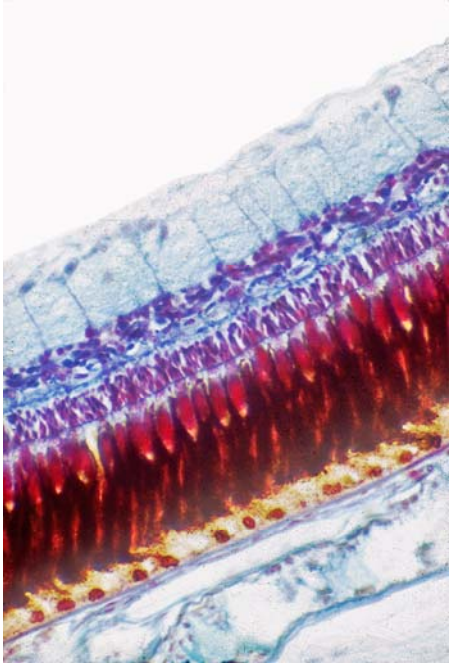

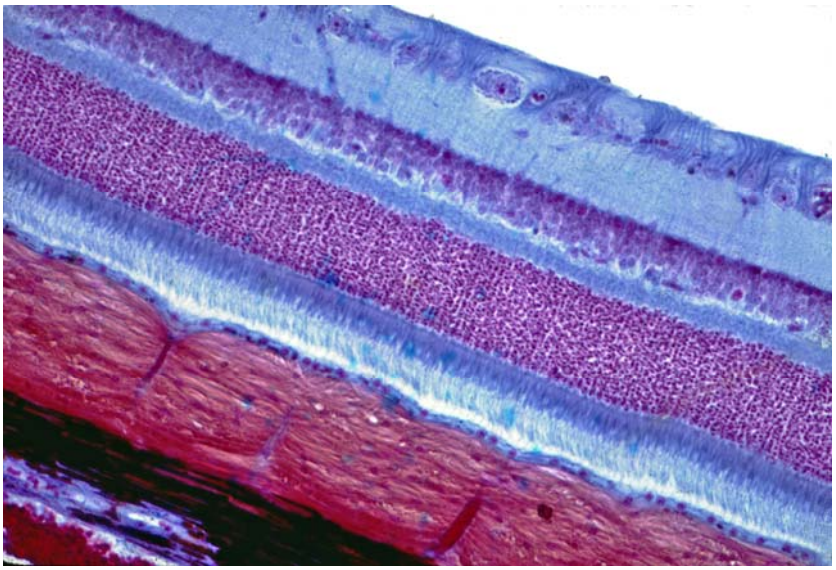

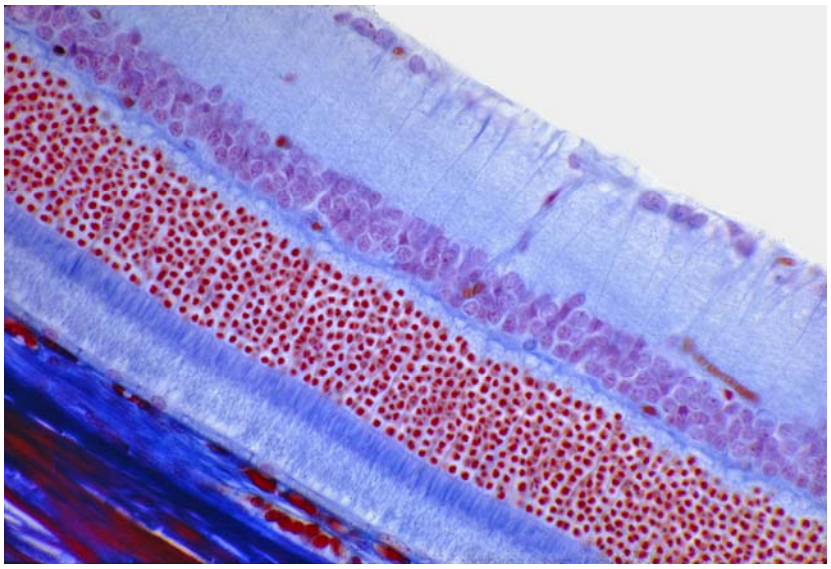

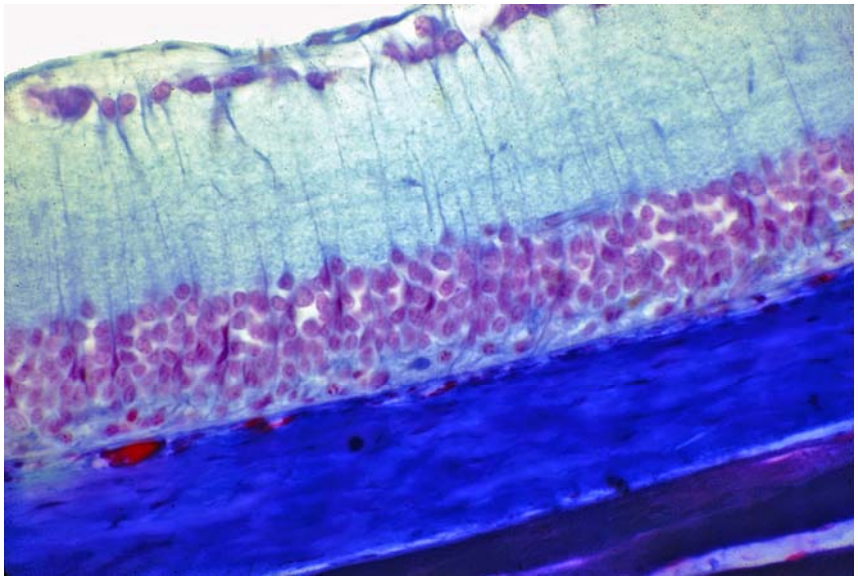

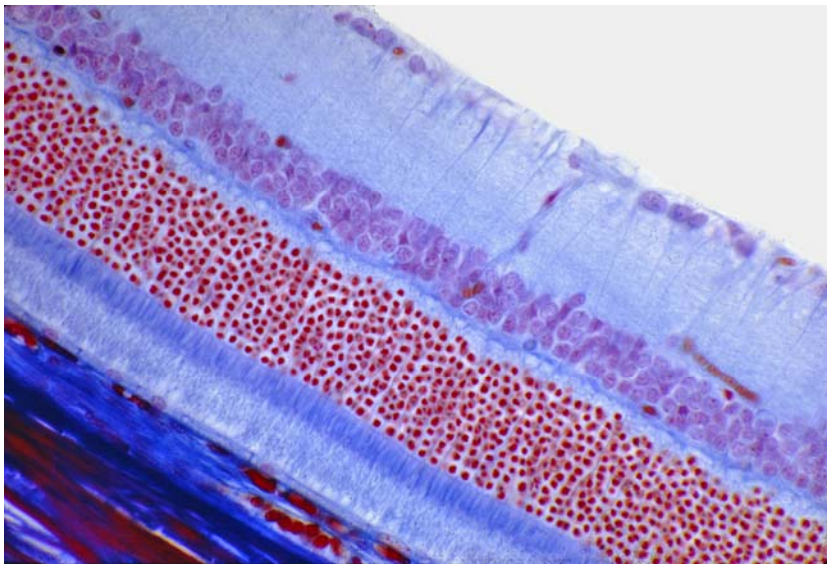

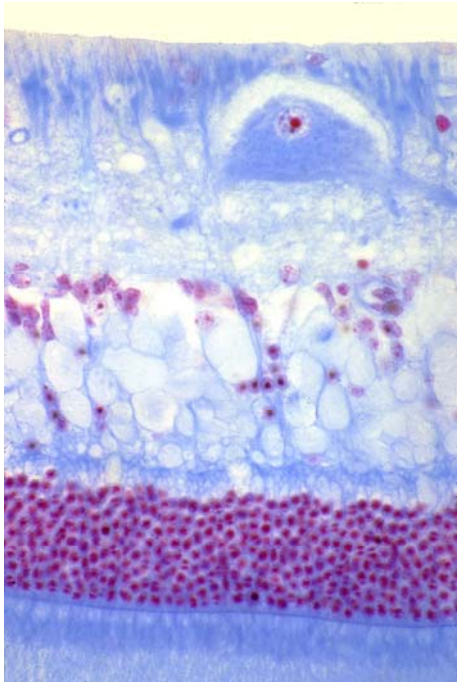

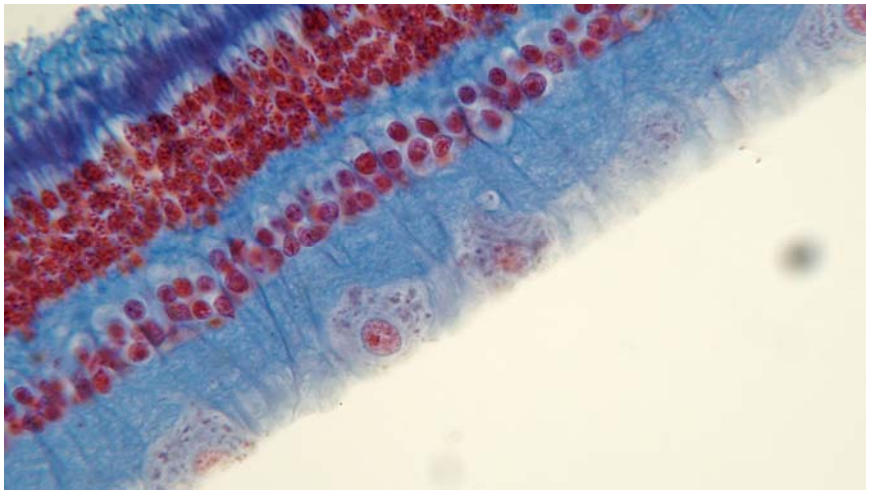

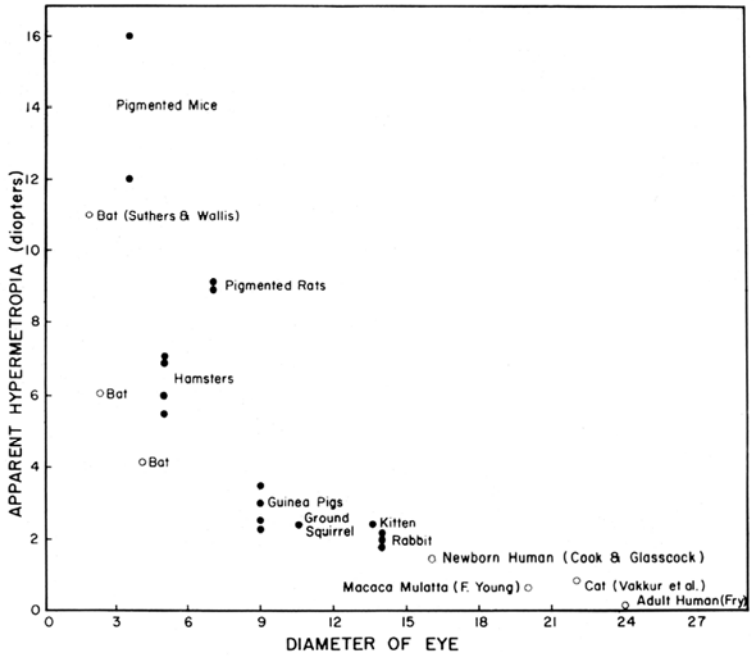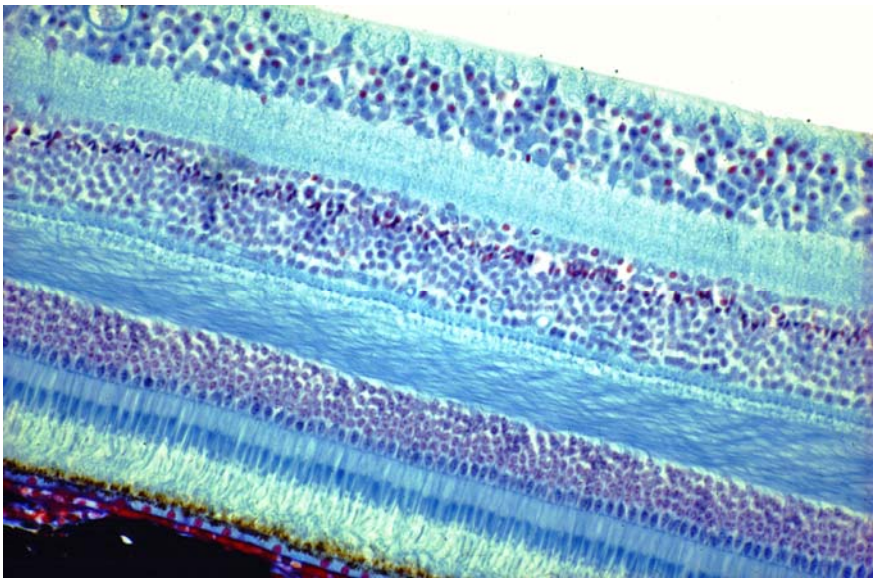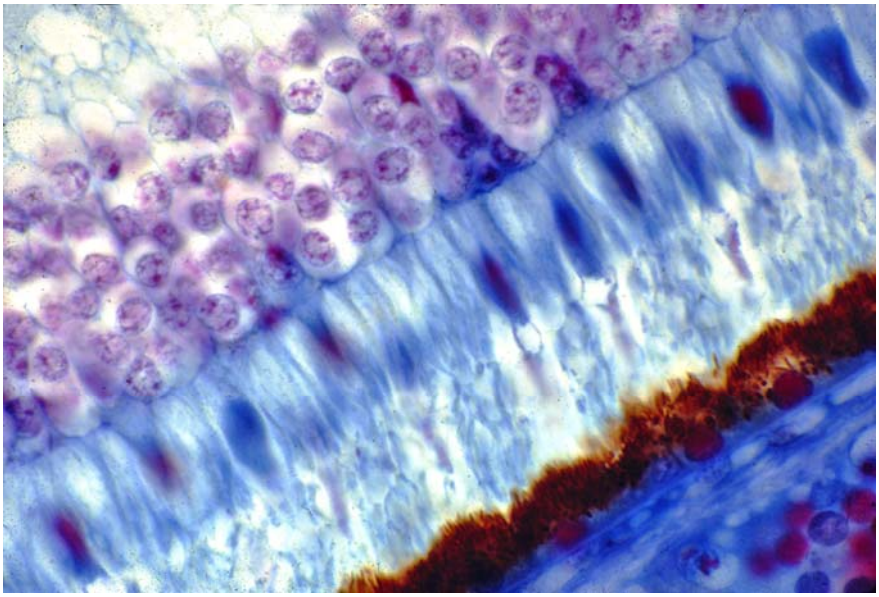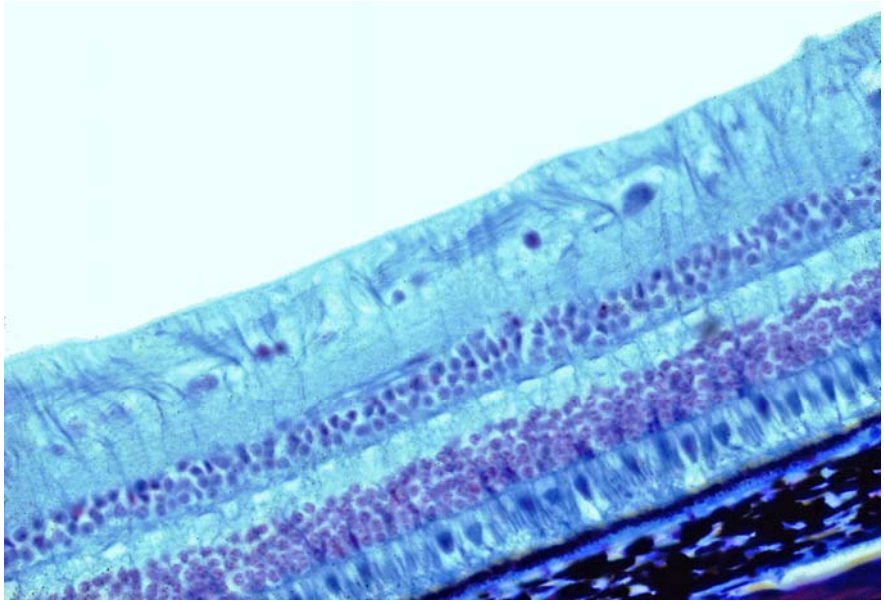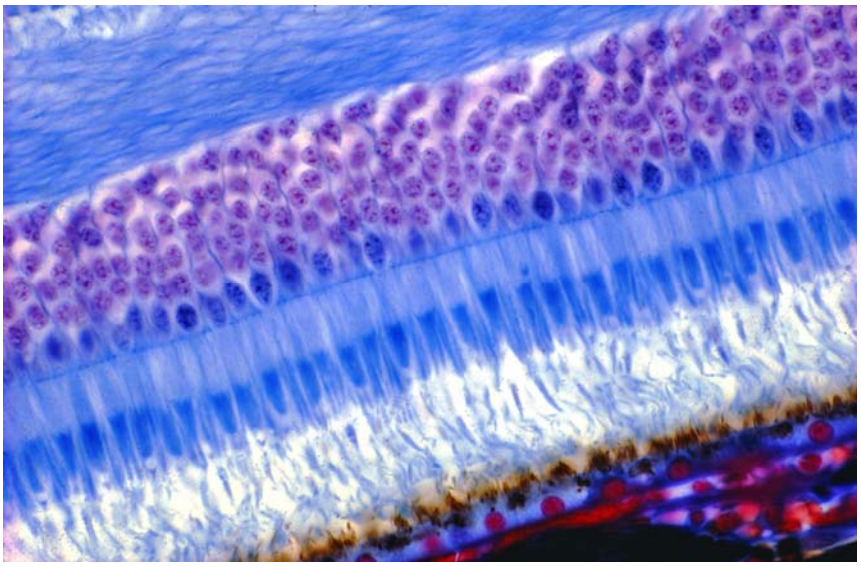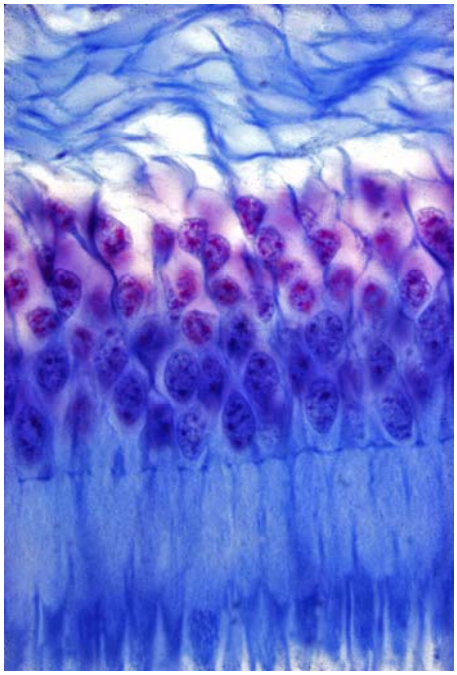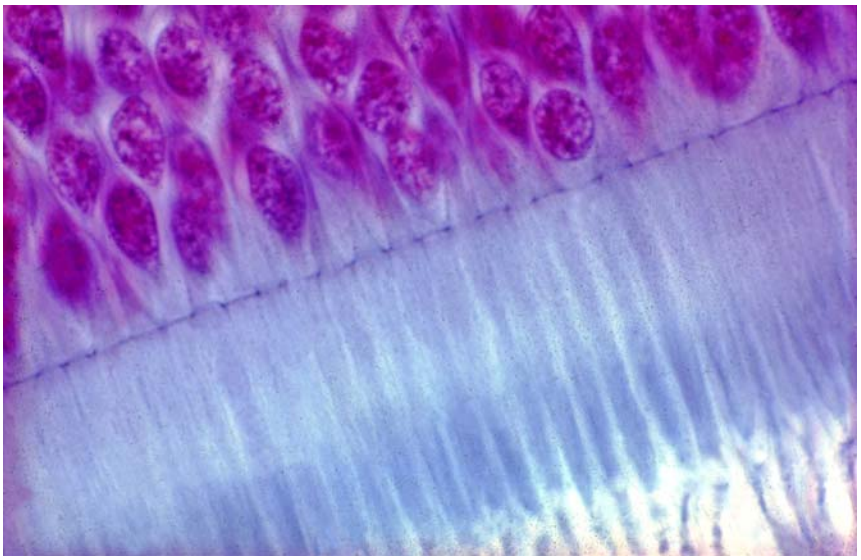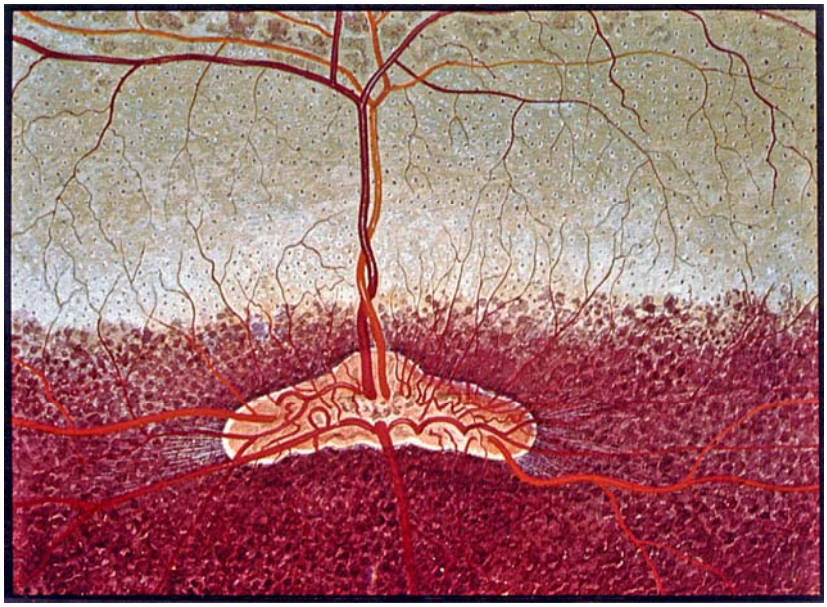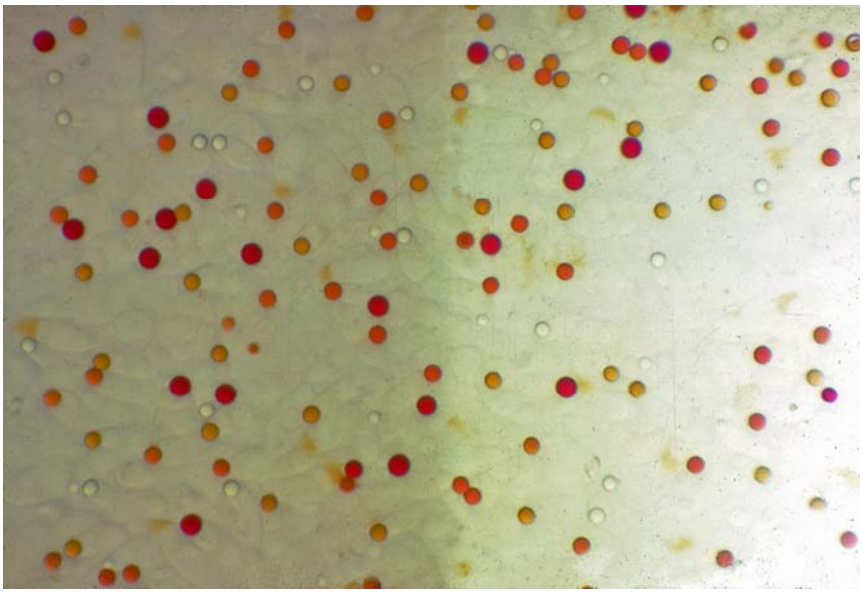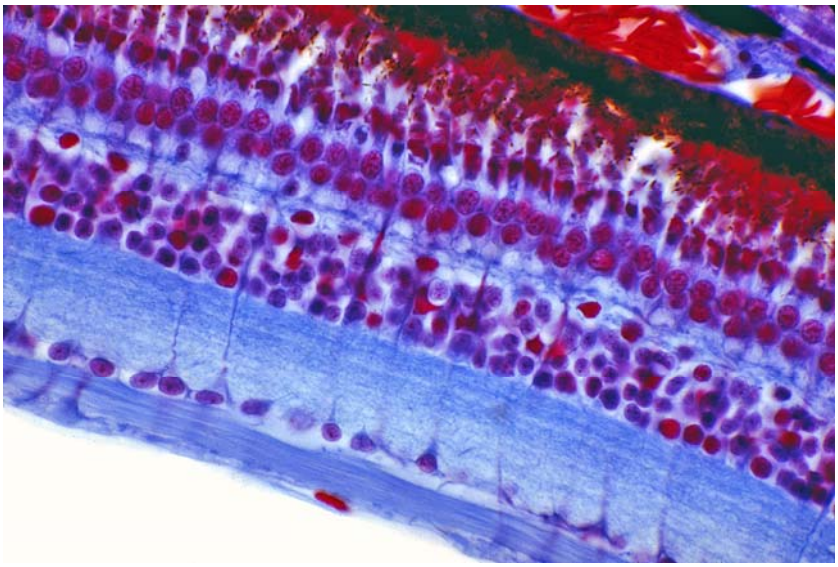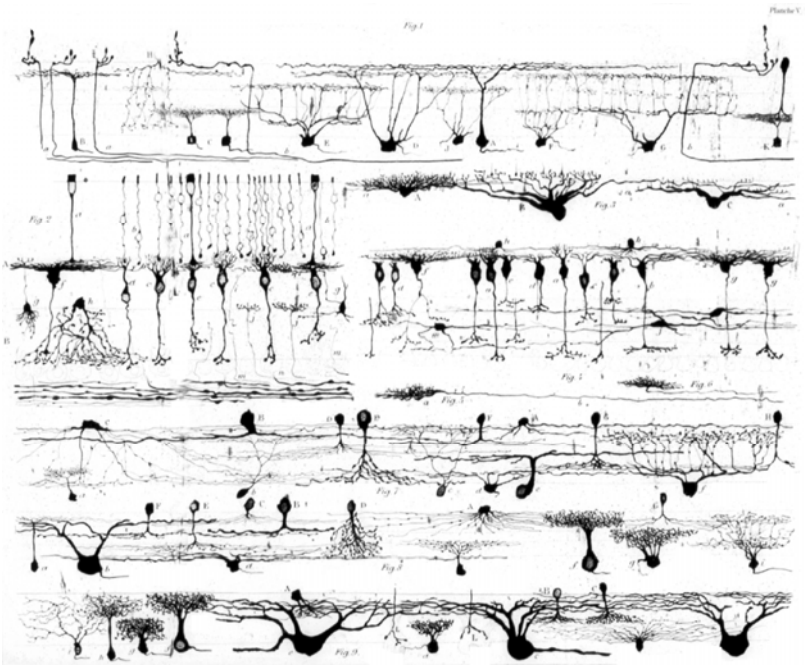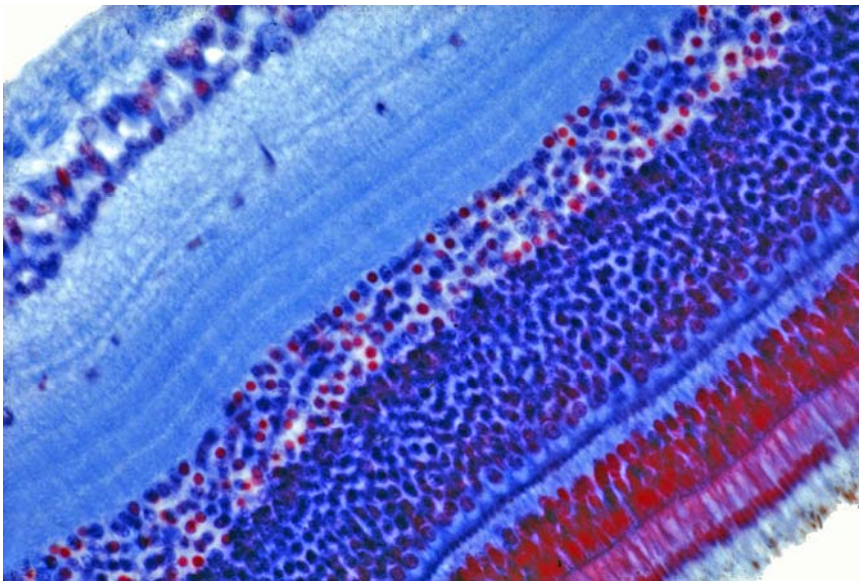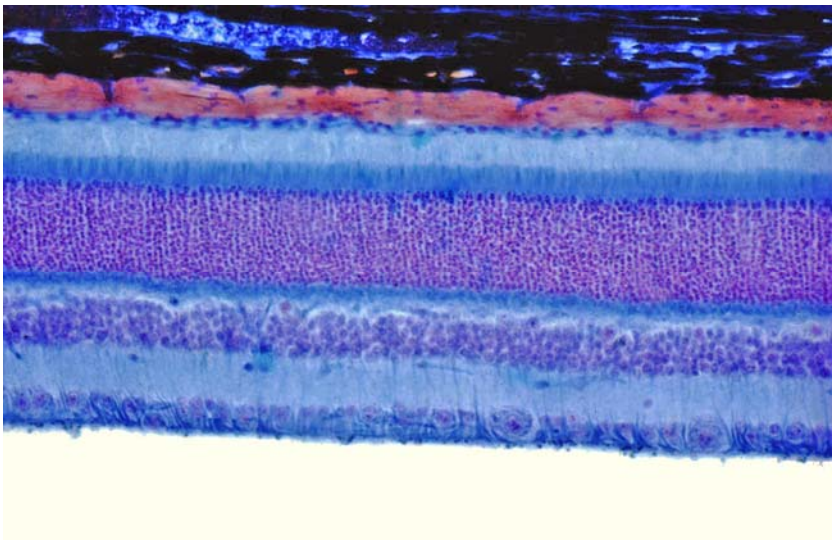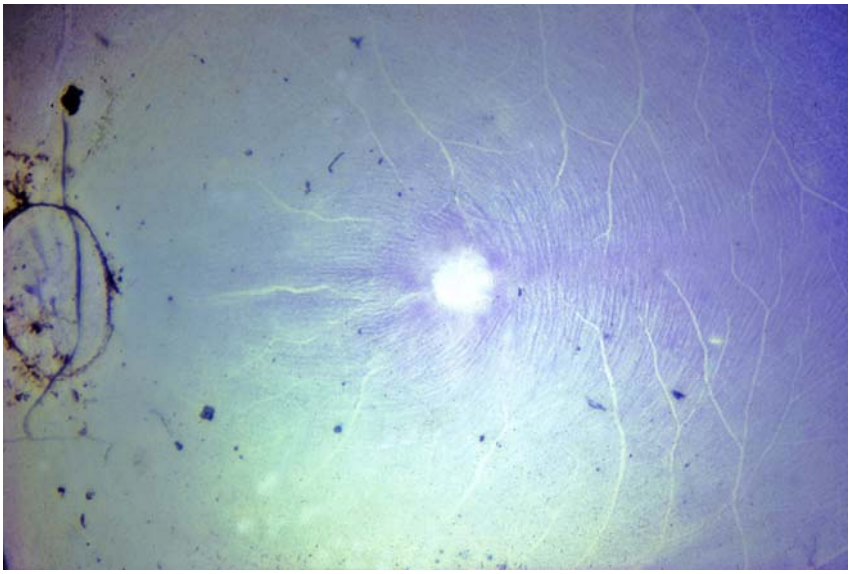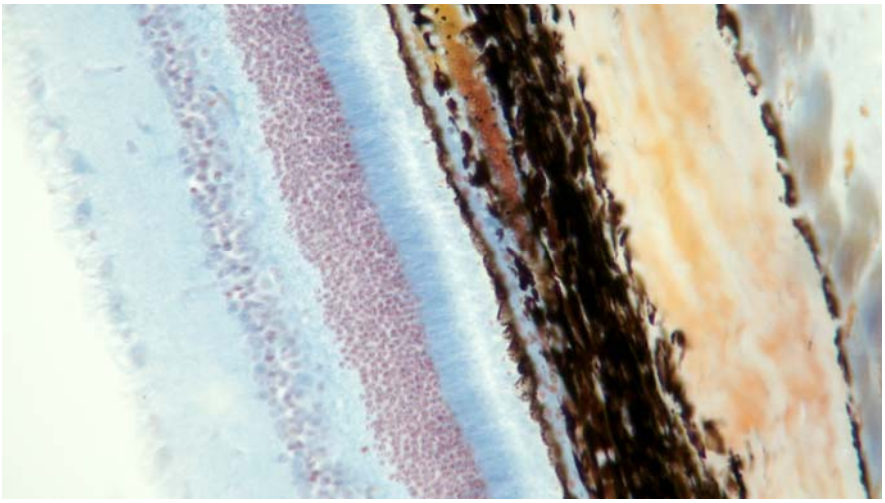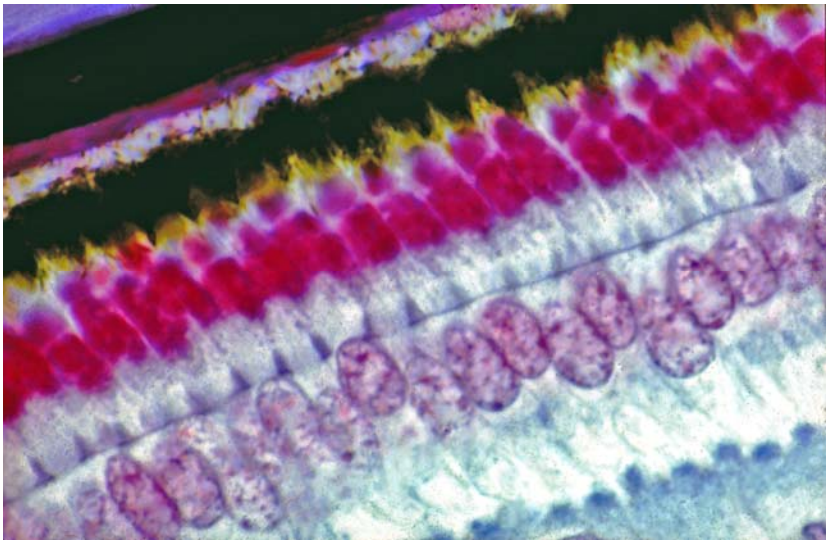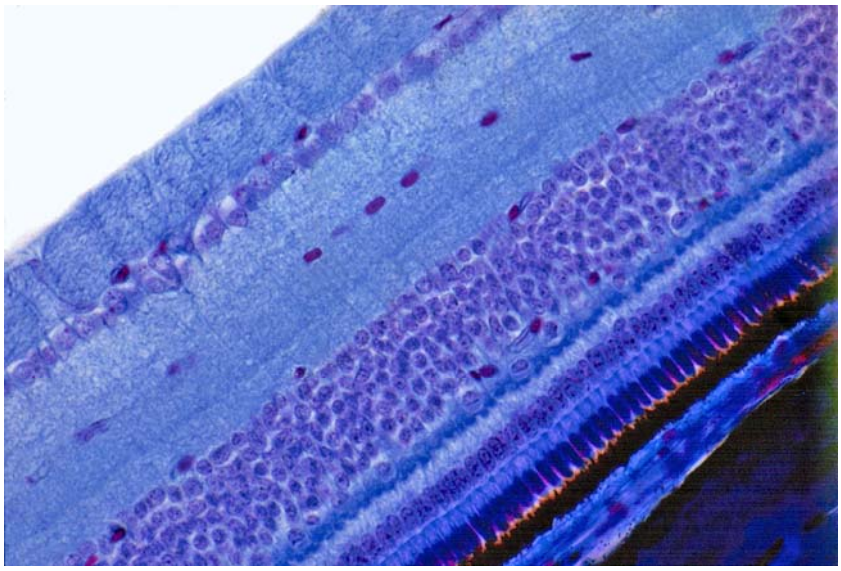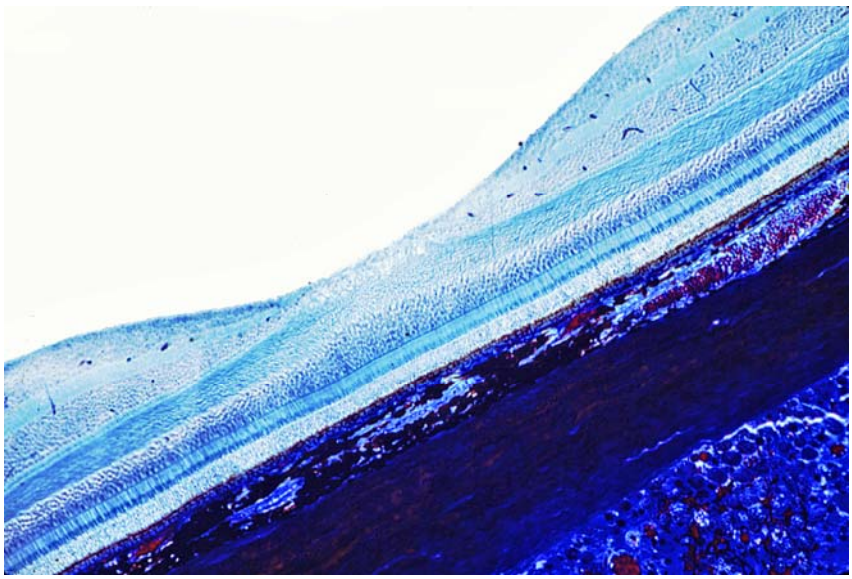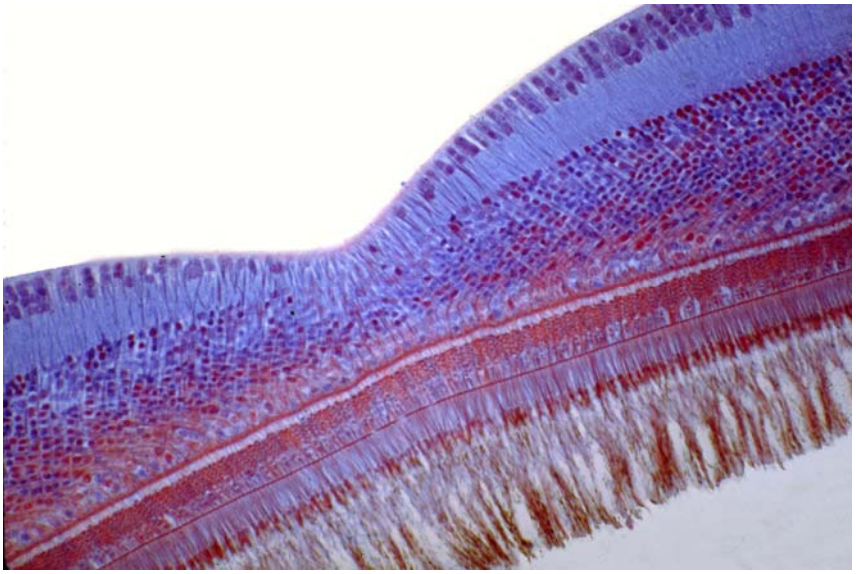
APPARENT HYPERMETROPIA (diopters)
DIAMETER OF EYE
Pigmented Mice
Bat (Suthers & Wallis)
Pigmented Rats
Hamsters
Bat
Bat
Guinea Pigs
Ground Squirrel
Kitten
Rabbit
Newborn Human (Cook & Glasscock)
Macaca Mulatta (F. Young)
Cat (Vakkur et al.)
Adult Human(Fry)